

## Caught sleeping: recording of snoring during a real-time MRI scan

Yoon-Chul Kim<sup>1</sup>, Michael I. Proctor<sup>2</sup>, Michael C.K. Khoo<sup>3</sup>, Shrikanth S. Narayanan<sup>1</sup>, and Krishna S. Nayak<sup>1</sup>

<sup>1</sup>Electrical Engineering, University of Southern California, Los Angeles, CA, United States, <sup>2</sup>Linguistics, University of Western Sydney, Sydney, Australia, <sup>3</sup>Biomedical Engineering and Pediatrics, University of Southern California, Los Angeles, CA, United States

**Introduction:** Real-time MRI of the upper airway has been used to study dynamics of vocal tract shaping during speech [1] as well as to identify airway collapse sites in subjects with obstructive sleep apnea (OSA) [2]. Snoring is an acoustic noise resulting from the vibration of the soft tissue in obstruction site(s) of the pharyngeal airway during sleep, and is a common precursor to OSA. Fiberoptic nasal endoscopy has been used to visualize the site(s) of obstruction in patients with OSA syndrome [3,4], but it is invasive and typically involves sedation-induced sleep [5]. In this work, we demonstrate simultaneous visualization of snoring and obstruction site during natural sleep using real-time MRI with synchronized audio recording and subsequent MRI noise cancellation.

**Methods:** We implemented a pulse sequence that allows for a control of ramp up/down of gradients, capable of gradual increase of acoustic noise (see Fig 1a), to facilitate subject's natural sleep onset. Experiments were performed on a GE 1.5T scanner (max gradient amplitude = 40 mT/m, max slew-rate = 150 T/m/s) with a custom 4-ch upper airway coil and a custom real-time imaging platform [6]. Two adult male subjects participated in the MRI study. Each subject lay supine. Each subject's head was immobilized with foam pads. An optical microphone was placed 5 to 10 cm anterior to the mouth. Imaging parameters: FOV = 24×24 cm<sup>2</sup>, slice thickness = 8 mm, spiral GRE, 30 spiral interleaves, 2.0×2.0 mm<sup>2</sup> resolution, 472.2 ms temporal resolution, TR = 15.74 ms. Gradient waveform design was made with a max gradient slew rate of 75 T/m/s. Scan was continuous for approximately 20 minutes. Image frames were obtained after a sliding window reconstruction with a frame rate 4.2 fps. Adaptive noise cancellation [7] was performed to reduce MRI gradient acoustic noise and obtain distinguishable snoring sounds.

**Results:** In one subject, we observed airway obstruction near the soft palate, accompanied by synchronized audio of snoring sound (see Fig 2). The retroglossal airway immediately superior to the tip of the epiglottis underwent a larger change anteroposteriorly than the retropalatal airway during sleep (see blue arrows in Fig 2a and 2c). An artifact was observed (see yellow arrow in Fig 2b) when there was a snoring event.

**Discussion:** Our preliminary results suggest that both airway obstruction site and snoring sound are detectable using real-time MRI with synchronized audio recording and subsequent noise cancellation. Improvements in the quality of the synchronized in-scanner audio recording will be necessary to better analyze the acoustic properties of snoring (see the noisy audio track in Fig 2d). One way of improving the performance of the MRI noise cancellation would be to reduce the periodicity of MRI acoustic noise (in our case, periodicity = 30×15.74 ms = 472.2 ms) by compromising the choices of FOV, spatial resolution, and gradient slew rate. Data acquired from more subjects involving more snoring events will be necessary to further examine the correlation between image artifact patterns and snoring (see Fig 2b). Current imaging protocols only provide a mid-sagittal view of the pharyngeal airway. Simultaneous imaging of multiple slices (e.g., mid-sagittal and coronal slices) [8] may contribute to better understanding and more sophisticated modeling of the relationship between the acoustics of snoring and airway constriction location [5].

**References:** [1] S Narayanan et al., J Acoust Soc Am. 2004;115:1771-1776. [2] L Shin et al., ISMRM 2011; p4634. [3] CB Croft and M Pringle, Clinical Otolaryngology 1991;16(5):504-509. [4] SJ Quinn et al., Clinical Otolaryngology 1995;20(4):360-364. [5] D Pevernagie et al., Sleep Medicine Reviews 2010;4:131-144. [6] J Santos et al., IEEE EMBS 2004;47:1048-1051. [7] E Bresch et al., J Acoust Soc Am 2006;120(4):1791-1794. [8] Y Kim et al., JMRI 2012;35(4):943-948.

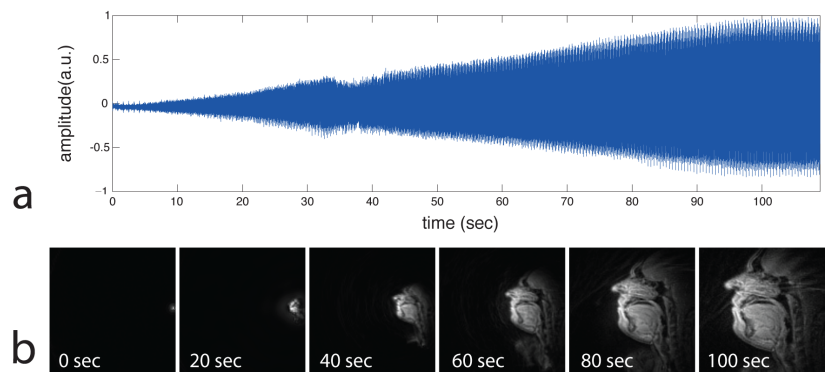


Figure 1. (a) Audio recording and (b) image frames at every 20 seconds during gradual ramp-up of gradients in a real-time MRI scan. Note that the gradient ramp-up increases acoustic noise and spatial resolution.

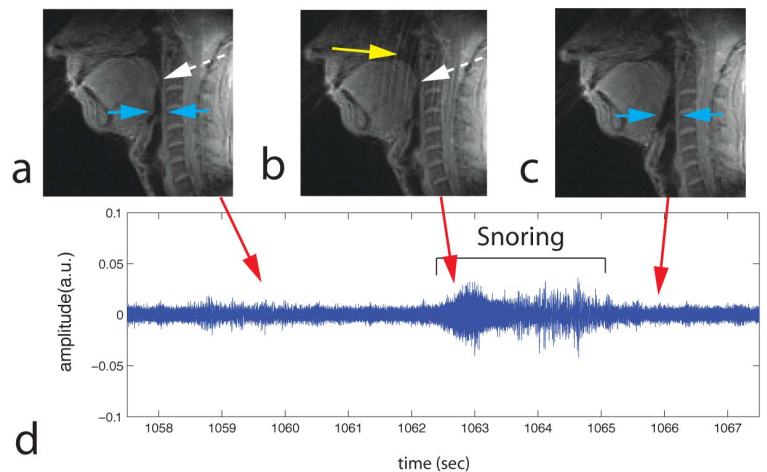


Figure 2. A snoring event detected by real-time MRI with synchronized audio recording. (a) Airway narrowing before snoring. The obstruction site is indicated by the white dashed arrow. (b) Airway narrowing during snoring. A wave-like image artifact is seen (see yellow arrow in (b)). (c) Enlarged airway after snoring. (d) A portion of audio track, which contains a snoring event, obtained after the MRI acoustic noise cancellation.